

**McLaren Flint**  
**Department of Radiology**  
**THYROID ULTRASOUND WORKSHEET**

**Patient risk factors (circle all that applies)**

Personal history of thyroid malignancy: Yes, No

Family history of thyroid malignancy: Yes, No

Personal history of radiation: Yes, No

Personal history of endocrine syndrome: Yes, No

**Indication for US (circle all that applies)**

Goiter                                      Palpable abnormality

Hypothyroid                                      Hyperthyroid

Other: \_\_\_\_\_

Incidental on CT MRI US PET (circle modality)

Prior ultrasound follow-up

Prior thyroid ultrasound: Yes (date/interval \_\_\_\_\_) No      Prior biopsy: Yes (date/interval \_\_\_\_\_) No

**ULTRASOUND FINDINGS**

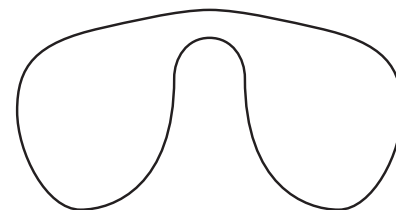
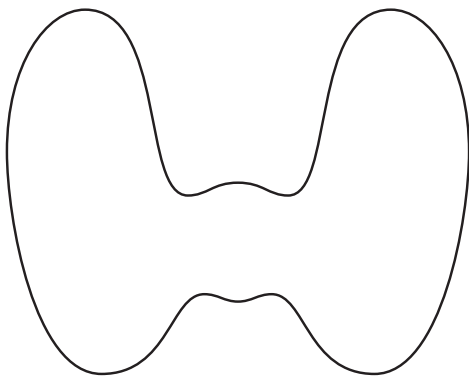
Technologist: \_\_\_\_\_

Size right lobe: \_\_\_\_\_ cm X \_\_\_\_\_ cm transverse X \_\_\_\_\_ cm anterior-posterior

Size left lobe: \_\_\_\_\_ cm craniocaudal X \_\_\_\_\_ cm transverse X \_\_\_\_\_ cm anterior-posterior

Size isthmus: \_\_\_\_\_ cm anterior-posterior

Overall texture (circle): Homogenous, Heterogenous



No.	IMAGES	SIZE (cm)	COMPOSITION	ECHOGENICITY	TALLER-THAN-WIDE	MARGINS	ECHOGENIC FOCI	TOTAL POINTS	TI-RADS LEVEL
		x x							
		x x							
		x x							
		x x							
		x x							
TWO largest Modules & any with IPORTANT FEATURES			C Cystic 0 Sp Spongiform 0 M Mixed cystic & nodule 1 S Solid 2 *If cystic or spongiform, do not add further points for other categories	^ Anechoic 0 ↑ Hyperechoic 1 = Isoechoic 1 ↓ Hypoechoic 2 ↓↓ Very Hypoechoic 3	No 0 Yes 3	S Smooth 0 ID Ill-defined 0 L Lobulated 2 I Irregular 2 E Extra-thyroidal ext 3	N None 0 CT Comet-Tail 0 M Macrocalc 1 PC Periph calc 2 P Punctate 3	0 pts TR1 Benign 2 pts TR2 Not Suspicious 3 pts TR3 Midly Suspicious 4-6 pts TR4 Mod Suspicious 7+ TR5 Highly Suspicious	